Hypothyroidism and Cerebral Infarction: A Case Report and Literature Review

Mei-Yuan Sun[1], Ta-Cheng Chen[2], and Yung-Lung Lee[3]

Abstract- Thyroid hormone has been studied in cardiovascular disease but rarely in cerebrovascular disease (CVD). Recently, hypothyroidism has been suggested to be related to risk factors such as atherosclerosis but not directly to CVD. We reported a 52-year-old woman with acute ischemic stroke, and greatly improved general conditions after thyroid hormone replacement. Hypothyroidism is reported to be one of the causes of hypertension or elevated cholesterol levels, the established risk factors of CVD. Further studies of the possible association of thyroid hormone and CVD are warranted. Thyroid hormone might need to be surveyed in CVD patients especially if there are symptoms and signs of thyroid disorders.

Key Words: Hypothyroidism, Cerebral infarction, Atherosclerosis

Acta Neurol Taiwan 2006;15:197-200

INTRODUCTION

Cerebrovascular disease (CVD) is the main cause of death and disability in adults. Risk factors for CVD include age, hypertension, cardiac diseases, diabetes mellitus, cigarette smoking, dyslipidemia; and, possibly also elevated C-reactive protein level and hyperhomocysteinemia. Hypothyroidism has been studied in cardiovascular disease but rarely mentioned in CVD patients. Here, we reported a patient diagnosed as acute stroke clinically, and with her neurological and general conditions improved greatly after thyroid hormone replacement. There may be growing evidence suggestive of the relationship between hypothyroidism and atherosclerosis. Hypothyroidism thus could be at least indirectly related to CVD.

CASE REPORT

A 52-year-old right-handed woman visited our outpatient department (OPD) of Neurology because of weakness of the left limbs and dysarthria for 2 days. She experienced one episode of consciousness impairment more than 10 years ago, slow gait for 2 years and mild dyspnea on exertion for some time. She has not been diagnosed with any systemic disease, has not had any operations, did not smoke or drink, and did not take any medication, herbs or pills. According to the patient's statement, sudden onset of left limbs weakness and dysarthria developed 2 days earlier when she was having ice cream that afternoon. The condition worsened on the next day but stabilized afterwards.

On admission, her vital sign was stable except tran-

From the Departments of Neurology, [1]Nantou Hospital, Department of Health, Executive Yuan; [2]Changhua Christian Hospital; [3]Department of Anesthesiology, Changhua Christian Hospital.
Received Febreary 2, 2005. Revised May 11, 2005.
Accepted February 3, 2006.

Reprint requests and correspondence to: Ta-Cheng Chen, M.D. P.O. BOX 5-25 Nantou, Nantou, Taiwan.
E-mail: drsunmaruco@yahoo.com.tw

sient elevation of the blood pressure (170/90 mmHg). Physical examination revealed a mild puffy face with edematous eyelids, a grade II/VI systolic murmur over the apex on cardiac auscultation, and mild nonpitting pretibial edema. A hoarse voice and dry as well as brittle hair was also noted. The patient was oriented on neurological examination, which revealed left central facial palsy, dysarthria, left hemiparesis (3/5 muscle strength diffusely) and hypesthesia of the left limbs. During hospitalization, laboratory studies revealed decreased Hgb (10.5 g/dl), T4 level (0.9 μg/dl), elevated Cholesterol (229 mg/dl) and ESR (97 mm/hr).

The chest film showed obvious cardiomegaly (Fig. 1), and brain CT showed a low density over the right corona radiata and old multiple infarcts in the right basal ganglia, the right corona radiata, and the pons (Fig. 2). Transthoracic cardiac echocardiography revealed regional wall motion abnormality, left ventricle dysfunction, mitral regurgitation, tricuspid regurgitation and pericardial effusion (350 ml). Ejection fraction was 33-43%.

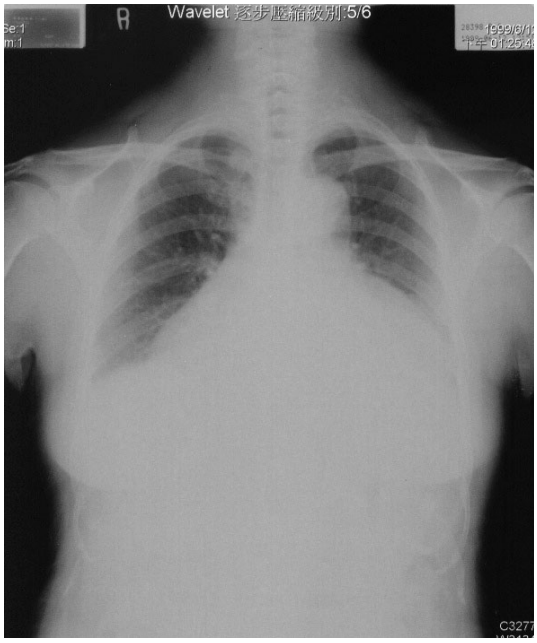

Figure 1. Before treatment, the chest film revealed obvious cardiomegaly in configuration.

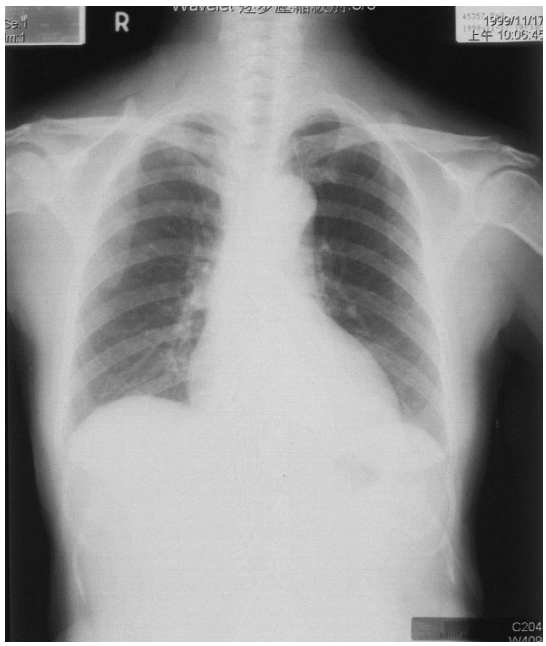

Figure 3. After thyroid hormone replacement 2-3 months later, the cardiomegaly was improved.

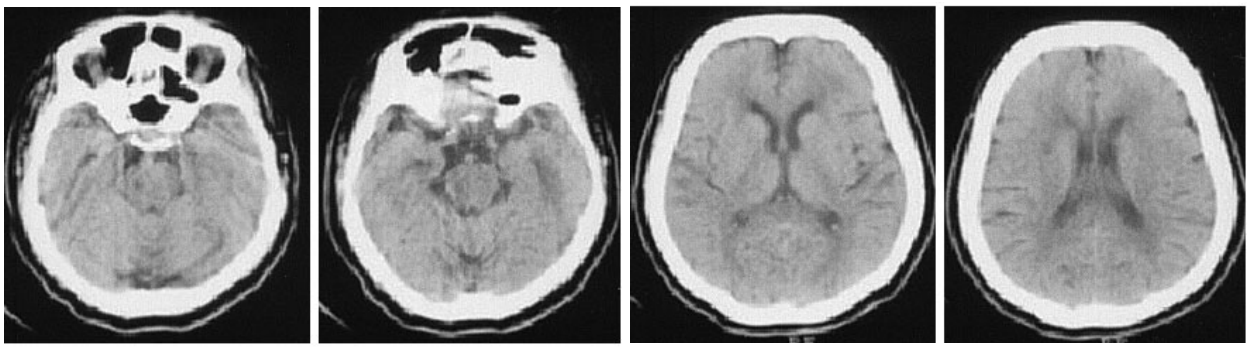

Figure 2. Brain CT showed a low density over the right corona radiata and old multiple infarcts in the right basal ganglia, the right corona radiate, and the pons.

Carotid duplex showed tortuosity of internal carotid artery and intima-media thickness (1.2 mm) in bilateral carotid bulbs, but there was no plaques or hemodynamic changes.

Further laboratory data showed Free T4 0.3 ng/dl, T3 0.4 ng/ml, TSH >75 uIU/ml, microsomal Ab 1:6400× (+) and cortisol (AM) 13.9 ug/dl. According to the clinical and laboratory data, autoimmune hypothyroidism was suspected and thyroxine sodium 0.05 mg per day was prescribed. The left hemiparesis and dysarthria recovered almost completely after the replacement therapy with thyroid hormones for 2-3 months. Cardiomegaly and shortness of breath are also improved (Fig. 3). After a two-year follow-up period, the patient had essentially no obvious neurological deficit.

DISCUSSION

The abnormality of the heart in this patient was obviously related to hypothyroidism. However, the abrupt onset of left-limbs weakness, left facial palsy, and dysarthria was compatible with a diagnosis of cerebrovascular disease rather than hypothyroidism, as the latter usually presented with an insidious onset of general weakness. Thyroid hormone influences cardiac performance via changes in peripheral circulation and is related to an increased risk of functional cardiovascular abnormalities and atherosclerosis[1-3]. Ischemic stroke is rarely mentioned in patients with hypothyroidism except in Hashimoto thyroiditis. In Hashimoto encephalopathy, a stroke-like pattern with mild cognitive impairment or a diffuse progressive type with seizures, psychotic episodes, and dementia has been noted. The pathogenesis is unclear but autoimmune-mediated inflammatory attack of cerebral vessels probably played a role[4]. However, our patient did not have Hashimoto thyroiditis.

Possible association between hypothyroidism and cerebral infarction

Many articles elaborated on the roles of the risk factors of cardiovascular disease or atherosclerosis in hypothyroidism. There is substantial evidence that hypothyroidism alters several risk factors of cardiovascular disease, including hypertension and hypercholesterolemia which may result in accelerated atherosclerosis and premature cardiovascular abnormalities. In recent years, hyperhomocysteinemia and endothelial dysfunction have also been identified as risk factors for atherosclerosis in patients with thyroid hormone deficiency[3,5-7].

Elevated level of lipoprotein(a) [Lp(a)], a particular atherogenic LDL variant, has also been reported in hypothyroidism and is considered as an independent risk factor for atherosclerosis[5]. Jurgens et al. showed that Lp(a) and total as well as low-density lipoprotein cholesterol were statistically significantly elevated, and the elevation could be correlated with the severity of symptomatic cerebrovascular disease and the degree of carotid stenosis[8].

In 1969, McCully proposed that elevated plasma homocysteine could cause atherosclerotic vascular disease[9]. Abundant epidemiologic evidence has validated this relationship and shown that hyperhomocysteinaemia is a common, independent risk factor for premature atherosclerotic and thromboembolic disorders such as cerebrovascular disease, coronary artery disease and venous thrombosis[10-14]. Acute hyperhomocysteinemia causes endothelial dysfunction, which might promote atheroma development and is associated with asymptomatic carotid artery wall thickening and stenosis[15-17]. Several studies had demonstrated elevated homocysteine levels in hypothyroidism, suggesting a potential mechanism for the higher incidence of vascular disease observed in patients with hypothyroidism[6,7,10].

Our patient did not have diabetes mellitus and the known risk factor of her ischemic stroke was hypercholesterolemia. There was increased IMT, but no plaque formation in the carotid duplex study or vegetation in the transthoracic echocardiography. There was no evidence to suggest that atherosclerosis with thrombosis is the cause of stroke in this patient from the lab work-up. Also, the negative results of transthoracic echocardiography, normal cardiac rhythm, and lack of past history of heart disease made cardiac emboli an unlikely cause. The improvement of the heart function (cardiomegaly) and her neurological condition two to three months after thyroid hormone therapy suggested that the event might

be related to hypothyroidism. Therefore, any ischemic stroke patient with possible manifestations of hypothyroidism should have thyroid function check-up and be treated with thyroid hormone as early as possible. Moreover, further large-scaled studies of the relationship between hypothyroidism and ischemic stroke are warranted.

REFERENCES

1. Klein I, Ojamaa K. Thyroid hormone and the cardiovascular system. N Engl J Med 2001;344:501-9.
2. Bengel FM, Nekolla SG, Ibrahim T, et al. Effect of thyroid hormones on cardiac function, geometry, and oxidative metabolism assessed noninvasively by positron emission tomography and magnetic resonance imaging. J Clin Endocrinol Metab 2000;85:1822-7.
3. Biondi B, Klein I. Hypothyroidism as a risk factor for cardiovascular disease. Endocrine 2004;24:1-14.
4. Nolte KW, Unbehaun A, Sieker H, et al. Hashimoto encephalopathy: a brainstem vasculitis? Neurology 2000; 54:769-70.
5. Cappola AR, Ladenson PW. Hypothyroidism and atherosclerosis. J Clin Endocrinol Metab 2003;88:2438-44.
6. Christ-Crain M, Meier C, Guglielmetti M, et al. Elevated C-reactive protein and homocysteine values: cardiovascular risk factors in hypothyroidism? A cross-sectional and a double-blind, placebo-controlled trial. Atherosclerosis 2003;166:379-86.
7. Nedrebo BG, Ericsson UB, Nygard O, et al. Plasma total homocysteine levels in hyperthyroid and hypothyroid patients. Metabolism 1998;47:89-93.
8. Jurgens G, Taddei-Peters WC, Koltringer P, et al. Lipoprotein(a) serum concentration and apolipiprotein(a) phenotype correlate with severity and presence of ischemic cerebrovascular disease. Stroke 1995;26:1841-8.
9. McCully KS. Vascular pathology of homocysteinemia: implications for the pathogenesis of arteriosclerosis. Am J Pathol 1969;56:111-28.
10. McCully KS. Homocysteine and vascular disease. Nat Med 1996;2:386-9.
11. Welch GN, Loscalzo J. Homocysteine and atherothrombosis. N Engl J Med 1998;338:1042-50.
12. Ueland PM, Refsum H, Brattstrom L. Plasma homocysteine and cardiovascular disease. In: Francis RB Jr, ed. Atherosclerotic Cardiovascular Disease, Hemostasis, and Endothelial Function. New Jork: Marcel Dekker, 1992:183-236.
13. Sarkar PK, Lambert LA. Aetiology and treatment of hyperhomocysteinaemia causing ischaemic stroke. Int J Clin Pract 2001;55:262-8.
14. Diekman MJ, van der Put NM, Blom HJ, et al. Determinants of changes in plasma homocysteine in hyperthyroidism and hypothyroidism. Clin Endocrinol 2001;54: 197-204.
15. Chambers JC, McGregor A, Jean-Marie J, et al. Demonstration of rapid onset vascular endothelial dysfunction after hyperhomocysteinemia: an effect reversible with vitamin C therapy. Circulation 1999;99:1156-60.
16. Selhub J, Jacques PF, Bostom AG, et al. Association between plasma homocysteine concentrations and extracranial carotid-artery stenosis. N Engl J Med 1995;332:286-91.
17. Malinow MR, Nieto FJ, Szklo M, et al. Carotid artery intimal-medial wall thickening and plasma homocysteine in asymptomatic adults. The Atherosclerosis Risk in Communities Study. Circulation 1993;87:1107-13.